



RESENTING CLINICAL SIGNS

DATE History: Possible increased respiratory rate. Radiographs showed cardiomegaly and possible pulmonary edema.

9/21/21

ECHOCARDIOGRAPHIC FINDINGS

2D, M-mode, and Doppler study.

PERFORMED BY:

Dr. Meredith Swart

Left atrial size is normal. The mitral valve is normal. Left ventricular wall thickness is normal. Left ventricular internal dimensions are normal. Left ventricular systolic function is hyperdynamic. The aorta and aortic valve appear normal. Right atrial and right ventricular dimensions are normal.

INTERPRETED BY

The tricuspid valve is normal. The pulmonary artery and pulmonic valve are normal. No shunting lesions are visualized. No pericardial effusion or cardiac masses are seen.

Keith Blass, DVM,
MS, DACVIM
(Cardiology)

LA/Ao - 1.32
IVSd - 4.1 mm
LVPWd - 3.7 mm
LVIDd - 11.9 mm
LVIDs - 4.6 mm
FS - 61%

PATIENT

Lali Langford

LVOT - 0.67 m/s
RVOT - 0.82 m/s

SPECIES ASSESSMENT/RECOMMENDATIONS

Normal echocardiogram

Feline

This examination demonstrates no evidence of structural heart disease. While I haven't seen Lali's radiographs, the absence of abnormalities in this exam suggests that her increased respiratory rate and possible pulmonary infiltrate are unlikely to be cardiogenic in origin.

BREED

No therapy appears to be indicated based on this exam.

DLH

A recheck echocardiogram is recommended if new physical exam and/or clinical abnormalities suggestive of cardiac dysfunction develop.

SEX

FS

AGE

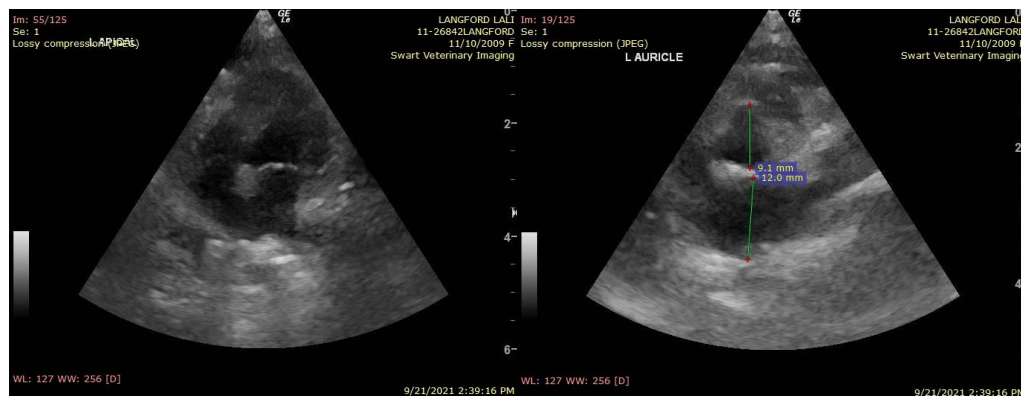12 y

WEIGHT

10 lb

HOSPITAL NAME

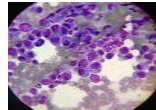
Swart Veterinary
Imaging



The information and recommendations provided are based on the images presented by the referring veterinarian. No evaluation can be communicated regarding pathology that was not visible in the image/video clips provided.

REFERRING VET

Dr. Swart



Thank you for this referral. If the clinical or image interpretation does not parallel your findings or if I can be of any further assistance please contact me.

DATE

9/21/21

Keith Blass, DVM, MS, DACVIM (Cardiology)
KeithBlass@gmail.com
631-804-5754

PERFORMED BY:

Dr. Meredith Swart

INTERPRETED BY

Keith Blass, DVM,
MS, DACVIM
(Cardiology)

PATIENT

Lali Langford

SPECIES

Feline

BREED

DLH

SEX

FS

AGE

12 y

WEIGHT

10 lb

HOSPITAL NAME

Swart Veterinary
Imaging

REFERRING VET

Dr. Swart